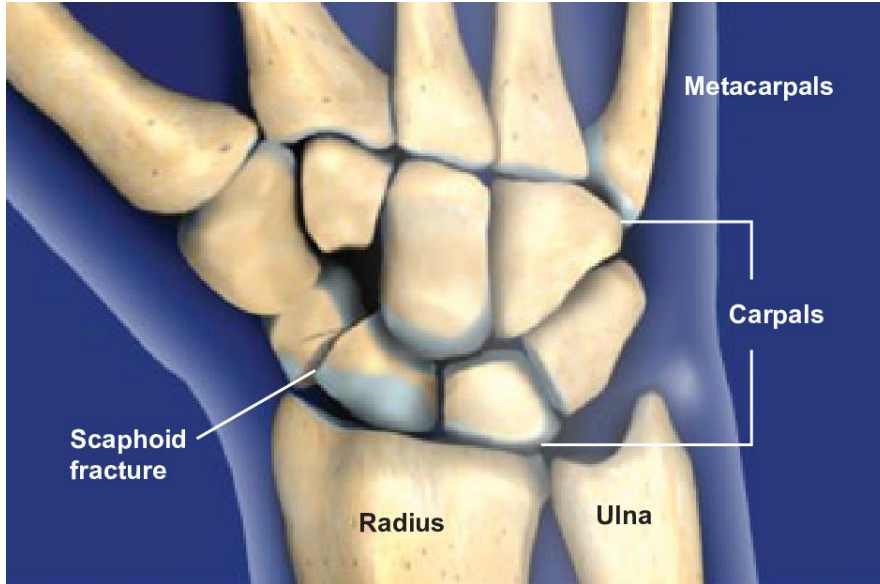




Scaphoid Fractures



Overview

A scaphoid fracture, one of the most common types of wrist fractures, is a break in the scaphoid bone. The scaphoid, one of the most important bones in the wrist, has a limited blood supply. An improperly treated scaphoid fracture can result in significant wrist pain, arthritis, and loss of motion.

Anatomy

The wrist is made up of eight carpal bones and the ends of the radius and ulna. The carpal bones are arranged in two rows between the radius, ulna, and the metacarpals. The scaphoid spans between both rows of carpals, coordinating motion between the radius and the carpal bones.

Causes

The most common cause of a scaphoid fracture is a fall onto an outstretched hand, which causes the wrist to hyperextend and rotate toward the thumb. This position puts tremendous force at the scaphoid, and can cause it to bruise, crack, or break into two or more pieces. Other common causes for scaphoid fracture include automobile, motorcycle or biking accidents and forceful blows to the wrist.

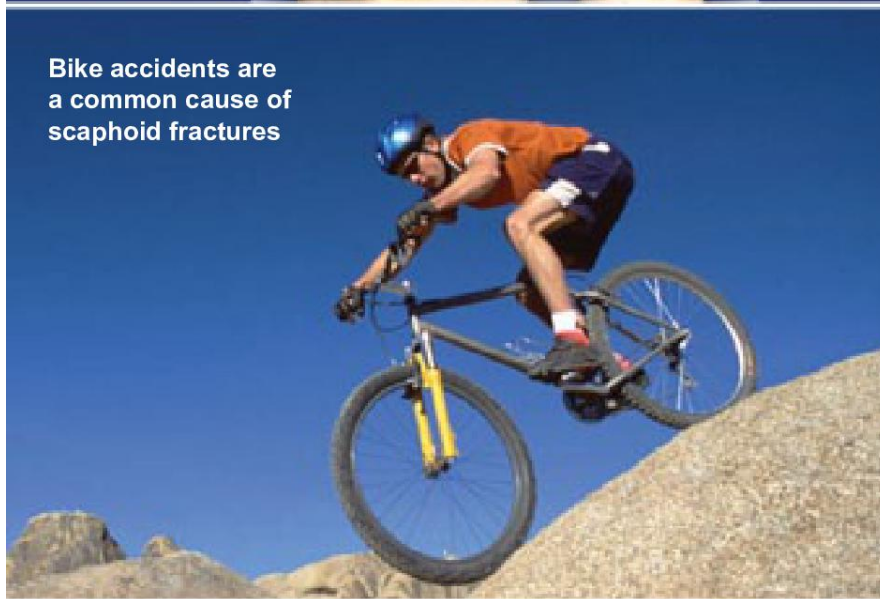
Symptoms

Scaphoid fractures are often mistaken for wrist sprains because they have similar symptoms. Symptoms include pain, difficulty with wrist movement and grip weakness. A key symptom of scaphoid fracture is tenderness over the scaphoid bone at the base of the thumb, which may be felt on the back or the palmar side of the hand. Swelling and bruising may also occur on the palmar side of the wrist. If the fracture is displaced, a painful crunching, popping, or shifting sensation may be felt when the wrist is moved.

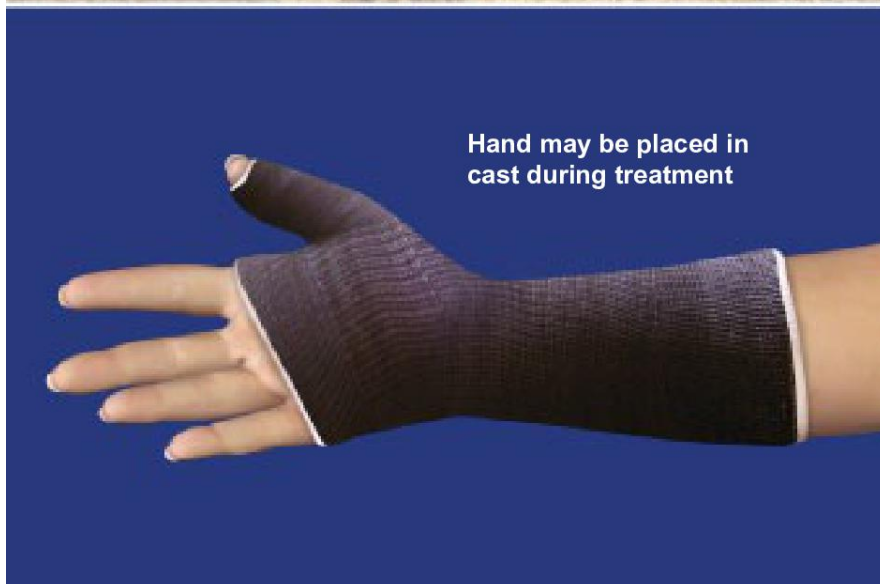Diagnosis

A scaphoid fracture is a serious problem that may be confused with a wrist sprain. X-rays are needed to identify scaphoid fractures. However, some non-displaced scaphoid fractures may not be visible on x-rays until a few weeks after the injury, so x-rays may need to be repeated. A bone scan, MRI or CT scan may also be required.

Bike accidents are a common cause of scaphoid fractures




Hand may be placed in cast during treatment





Scaphoid Fractures



Treatment

Treatment for scaphoid fractures depends on the fracture location and the presence of fracture displacement. Most nondisplaced scaphoid fractures will heal if treated in a cast for eight to twelve weeks. The cast usually includes the thumb, wrist, and forearm and may extend to or above the elbow. Some scaphoid fracture patterns do not heal well with cast treatment. For these fractures and displaced fractures, surgery will be necessary.