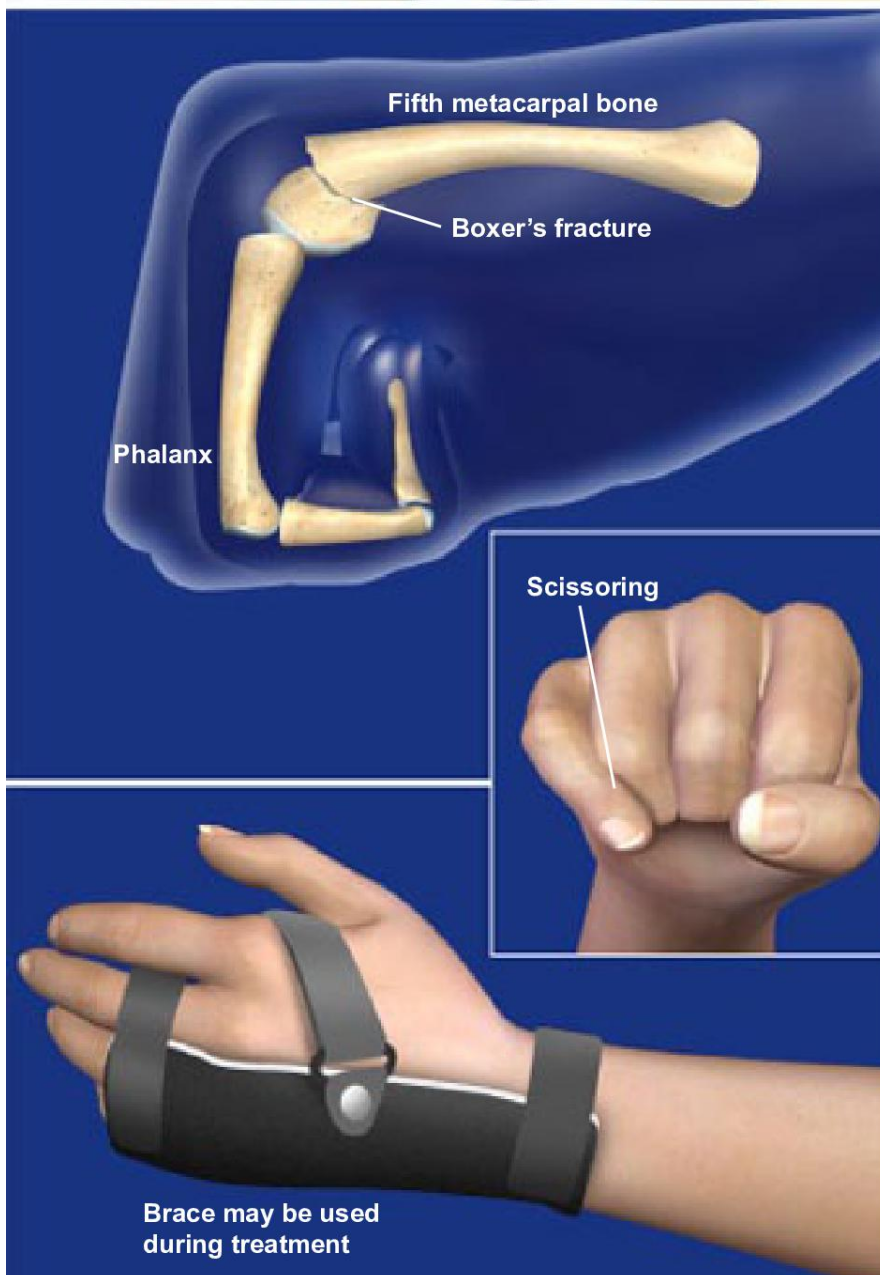




## Boxer's Fracture



### Overview

A boxer's fracture is a break of the metacarpal of the little finger. The metacarpals are the long bones in the hand that connect the fingers to the wrist. A boxer's fracture refers to a break at the end of the bone nearest the knuckle, which is called the metacarpal neck.

### Causes

This type of fracture most commonly occurs when someone punches a hard surface (or another person) with a closed fist. Since most people punch in a roundhouse fashion, the first point of boney contact in a punch is the little finger metacarpal bone. The force concentrates at the metacarpal neck, leading to a fracture. Ironically, this is a rare injury in boxers because they are trained to punch with even force over the entire hand, maximizing force and minimizing injury. A boxer's fracture can also occur when a person stumbles and tries to break his fall with a closed fist to the ground. Occasionally, direct trauma to the hand can also cause this injury.

### Symptoms

Common symptoms include pain, tenderness, and swelling around the knuckle of the little finger. Bruising and loss of knuckle contour are also common, and extending the finger may be difficult. In severely displaced fractures, the fingers may overlap (or scissor) when they are flexed.

### Treatment

Most boxer's fractures can be treated with a cast or brace to stabilize the fracture while it heals. If the knuckle is severely deformed, a procedure called a closed reduction may be needed to push the fracture back into proper position before casting. For severe displacement, finger scissoring, or multiple metacarpal fractures, surgery may be recommended.